

Society Position Statement

Canadian Cardiovascular Society/Canadian Society of Cardiac Surgeons/Canadian Society for Vascular Surgery Joint Position Statement on Open and Endovascular Surgery for Thoracic Aortic Disease

Jehangir J. Appoo, MDCM (Co-chair),^a John Bozinovski, MD,^b Michael W.A. Chu, MD,^c Ismail El-Hamamsy, MD, PhD,^d Thomas L. Forbes, MD,^e Michael Moon, MD,^f Maral Ouzounian, MD, PhD,^g Mark D. Peterson, MD, PhD,^h Jacques Tittley, MD,ⁱ and Munir Boodhwani, MD, MSc (Co-chair);^j on behalf of the CCS/CSCS/CSVS Thoracic Aortic Disease Guidelines Committee

^aDivision of Cardiac Surgery, Libin Cardiovascular Institute, Cumming School of Medicine, University of Calgary, Calgary, Alberta, Canada

^bDivision of Cardiac Surgery, Royal Jubilee Hospital, University of British Columbia, Victoria, British Columbia, Canada

^cDivision of Cardiac Surgery, London Health Sciences Center, London, Ontario, Canada

^dDivision of Cardiac Surgery, Montreal Heart Institute, Université de Montréal, Montréal, Québec, Canada

^eDivision of Vascular Surgery, University of Toronto, Toronto, Ontario, Canada

^fDivision of Cardiac Surgery, University of Alberta, Edmonton, Alberta, Canada

^gDivision of Cardiac Surgery, University Health Network, Toronto, Ontario, Canada

^hDivision of Cardiac Surgery, St Michael's Hospital, Toronto, Ontario, Canada

ⁱDivision of Vascular Surgery, Hamilton Health Sciences Center, Hamilton, Ontario, Canada

^jDivision of Cardiac Surgery, University of Ottawa Heart Institute, Ottawa, Ontario, Canada

ABSTRACT

In 2014, the Canadian Cardiovascular Society (CCS) published a position statement on the management of thoracic aortic disease addressing size thresholds for surgery, imaging modalities, medical therapy, and genetics. It did not address issues related to surgical intervention. This joint Position Statement on behalf of the CCS, Canadian Society of Cardiac Surgeons, and the Canadian Society for Vascular Surgery provides recommendations about thoracic aortic

RÉSUMÉ

En 2014, la Société canadienne de cardiologie (SCC) a publié un énoncé de position sur la prise en charge de la maladie de l'aorte thoracique où elle traitait notamment des seuils de diamètre aortique justifiant une chirurgie, des modalités d'imagerie médicale, des traitements médicaux et des considérations génétiques, mais n'abordait pas les questions relatives aux interventions chirurgicales. Le présent énoncé de position conjoint de la SCC, de la Société

Received for publication November 9, 2015. Accepted December 7, 2015.

Corresponding author: Dr Munir Boodhwani, Division of Cardiac Surgery, University of Ottawa Heart Institute, H3405, 40 Ruskin St, Ottawa, Ontario K1Y 4W7, Canada. Tel.: +1-613-761-4313; fax: +1-613-761-5107.

E-mail: mboodhwani@ottawaheart.ca

The disclosure information of the authors and reviewers is available from the CCS on their guidelines library at www.ccs.ca.

This statement was developed following a thorough consideration of medical literature and the best available evidence and clinical experience. It represents the consensus of a Canadian panel comprised of multidisciplinary experts on this topic with a mandate to formulate disease-specific recommendations. These recommendations are aimed to provide a reasonable and practical approach to care for specialists and allied health professionals obliged with the duty of bestowing optimal care to patients and families, and can be subject to change as scientific knowledge and technology advance and as practice patterns evolve. The statement is not intended to be a substitute for physicians using their individual judgment in managing clinical care in consultation with the patient, with appropriate regard to all the individual circumstances of the patient, diagnostic and treatment options available and available resources. Adherence to these recommendations will not necessarily produce successful outcomes in every case.

disease interventions, including: aortic valve repair, perfusion strategies for arch repair, extended arch hybrid reconstruction for acute type A dissection, endovascular management of arch and descending aortic aneurysms, and type B dissection. The position statement is constructed using Grading of Recommendations Assessment, Development and Evaluation (GRADE) methodology, and has been approved by the primary panel, an international secondary panel, and the CCS Guidelines Committee. Advent of endovascular technology has improved aortic surgery safety and extended the indications of minimally invasive thoracic aortic surgery. The combination of safer open surgery with endovascular treatment has improved patient outcomes in this rapidly evolving subspecialty field of cardiovascular surgery.

canadienne des chirurgiens cardiaques et de la Société canadienne de chirurgie vasculaire fournit des recommandations relatives aux interventions chirurgicales pour le traitement de la maladie de l'aorte thoracique, notamment la réparation de la valve aortique, les stratégies de perfusion pour la réparation de la crosse de l'aorte, la reconstruction hybride étendue de la crosse de l'aorte suivant une dissection aiguë de type A de même que la prise en charge endovasculaire des anévrismes de la crosse de l'aorte, des anévrismes de l'aorte descendante et des dissections aortiques de type B. Cet énoncé de position a été élaboré à l'aide de la méthode GRADE (*Grading of Recommendations Assessment, Development and Evaluation*) et a été approuvé par le comité chargé du projet, un comité international et le comité des lignes directrices de la SCC. La prise en charge endovasculaire a permis d'élargir le champ des interventions aortiques minimalement invasives et ainsi de réduire les risques pour les patients. La combinaison de la chirurgie ouverte plus sûre et de la prise en charge endovasculaire a amélioré les issues de traitement des patients et a donné lieu à une évolution très rapide de cette spécialité de la chirurgie cardiovasculaire.

Thoracic aortic disease management is a rapidly evolving as a subspecialty interest. Recent improvements in open and endovascular surgery have resulted in formation of new paradigms. In response, a multispecialty panel from the Canadian Society of Cardiac Surgeons and the Canadian Society for Vascular Surgery was struck to develop recommendations on thoracic aortic disease interventions. The methodology included a literature review using existing systematic reviews and meta-analyses when available, as well as new data

summaries to inform recommendations. The primary panel approved the recommendations and the document was peer-reviewed by an international secondary panel and the Canadian Cardiovascular Society Guidelines Committee. The resulting document is not an exhaustive review of all thoracic aortic procedures, but rather focuses on certain emerging and novel thoracic aortic disease interventions. Recommendations were developed using Grading of Recommendations Assessment, Development and Evaluation (GRADE) methodology,¹

AI Class	Type I Normal cusp motion with Functional Aortic Annulus dilatation			Type II Cusp Prolapse	Type III Cusp Restriction
	Ia	Ib	Ic		
Mechanism					
Repair Techniques (Primary)	STJ remodeling <i>Ascending aortic graft</i>	Aortic Valve sparing: <i>Reimplantation or Remodeling with SCA</i>	SCA	Prolapse Repair <i>Plication</i> <i>Triangular resection</i> <i>Free margin Resuspension</i> <i>Patch</i>	Leaflet Repair <i>Raphé Shaving</i> <i>Decalcification</i> <i>Patch</i>
(Secondary)	SCA		STJ Annuloplasty	SCA	SCA

Figure 1. Repair-oriented classification of aortic insufficiency (AI). SCA, subcommissural annuloplasty; STJ, sinotubular junction. Reprinted from Boodhwani et al.³ with permission from Elsevier.

with values and preferences to provide context to the recommendations. Our target audience includes all stakeholders involved in the surgical and endovascular management of thoracic aortic disease as well as other clinicians who care for these patients.

Aortic Valve Preservation and Repair

Aortic valve function is intimately linked to the anatomy of the aortic root and the ascending aorta.² Diseases that affect the aortic root and ascending aorta are, therefore, frequently associated with valvular disease, commonly aortic insufficiency (AI). Mechanisms of AI in up to 50% of patients can include dilatation of the sinotubular junction and the ventriculoaortic junction (Fig. 1).³ Cusp disease, in the form of cusp prolapse or restriction might further contribute to AI. Patients with aortopathy might also present with aortic valve stenosis. This is frequently observed in patients with bicuspid aortic valve, which is associated with aortic dilatation because of genetic, molecular, or hemodynamic reasons.^{4,5}

Traditional surgical treatment of aortic root aneurysms, with or without associated valve disease, consisted of composite replacement of the aortic valve and root with reimplantation of the coronary arteries, also known as the Bentall procedure. In contrast, preservation of the native aortic valve potentially avoids or reduces the long-term complications associated with prosthetic aortic valves including thromboembolism, anticoagulation-related hemorrhage, endocarditis, and structural valve deterioration.⁶⁻⁸

Two of the most common approaches for valve-sparing aortic root replacement include the reimplantation and the remodelling procedures. In the reimplantation procedure, the Dacron graft used to replace the aortic root is anchored to the subannular region of the aortic valve, whereas in the remodelling approach, the graft is sewn to the rim of aortic tissue distal to the valve leaflet insertion, following the crown shape of the aortic annulus. Because of this difference, the reimplantation procedure might be more protective against future annular dilatation in patients with connective tissue diseases or bicuspid aortic valves. Outcome data, up to 15-20 years, have shown durability of valve-sparing aortic root procedures with 10-year freedom from repeat surgery of approximately 90% in most observational studies (Supplemental Tables S1 and S2).^{9,10} An important limitation is that most data come from few centres, typically from single-surgeon series, which limits the generalizability of the findings and might be prone to publication bias. Not all groups have reported uniformly durable results, including a prospective multicentre registry reporting a 7% recurrence of AI at 1 year after aortic valve-sparing root replacement in patients with Marfan syndrome.¹¹

A variety of techniques have emerged to treat cusp disease, and in particular cusp prolapse,¹² which is the most common cusp pathology responsible for AI. These cusp repair techniques have also been used in patients with bicuspid aortic valves with promising durability in selected observational studies over a 10- to 15-year follow-up interval.^{7,13} Valve-sparing root replacement with the reimplantation technique has also been shown to improve the durability of bicuspid aortic valve repair in patients with annular dilatation, even in the absence of aortic root aneurysms.¹⁴⁻¹⁶ Multiple cohort studies and systematic

reviews have confirmed that aortic valve repair is associated with a low surgical mortality (1%-2%) and a low risk of thromboembolism (0.4% per year), endocarditis (0.23% per year), and bleeding (0.23% per year).^{9,10} However, there are limited data available on durability beyond 15 years. In contrast, the Prospective Randomized On-X Anti-coagulation Clinical Trial (PROACT) trial,¹⁷ a multicentre trial on low vs high international normalized ratio (INR) strategies for a contemporary mechanical aortic valve prosthesis showed substantially higher risk of bleeding (2.7% per year in the low INR group; 6.6% per year in the high INR group) and thromboembolism (2.7% per year in the low INR group; 1.6% per year in the high INR group). Bioprosthetic aortic valve replacement is also associated with a high rate of structural valve deterioration in patients younger than 60 years of age with approximately 50% requiring repeat surgery at 8-10 years after implantation.¹⁸

RECOMMENDATION

1. We recommend aortic root and ascending aortic aneurysms in patients with normally functioning or mildly regurgitant trileaflet aortic valves be treated with valve-sparing procedures whenever feasible (Strong Recommendation, Medium-Quality Evidence).

Values and preferences. A composite valve and root replacement might be preferred in emergency settings, in elderly patients, in patients with multiple comorbidities, poor left ventricular function, or with poor-quality cusp tissue. A reimplantation approach to valve-sparing root replacement might be preferred in patients with connective tissue diseases and bicuspid aortic valves.

2. We suggest aortic root and ascending aortic aneurysms in patients with moderate or greater insufficiency with or without bicuspid aortic valves be considered for valve-sparing root replacement with or without cusp repair (Weak Recommendation, Low-Quality Evidence).

Values and preferences. Important considerations include surgeon experience, patient age and preference, quality of cusp tissue, and the ability to perform these procedures with mortality and morbidity similar to that in composite valve and root replacement procedures.

3. We suggest that, in patients who undergo bicuspid aortic valve repair with moderate aortic root dilatation, valve-sparing root replacement be considered to improve repair durability (Weak Recommendation, Low-Quality Evidence).

Values and preferences. Addition of an aortic root procedure should not increase the mortality and morbidity risk associated with the intervention.

Considerations for Aortic Valve Replacement in Young Patients With Aortic Dilatation

When aortic valve replacement is required with concomitant dilated aorta, a mechanical or biological prosthesis remains the gold standard in young adults and elderly patients.

Although there are no randomized controlled trials on outcomes using modern prostheses, there are several long-term cohort studies.¹⁸⁻²⁴ Prosthetic aortic valve replacement offers the advantages of a reproducible procedure with low perioperative morbidity and mortality. Disadvantages relate to long-term concerns with patient survival,^{18,19} rates of valve-related complications (endocarditis, thromboembolism, major bleeding, or repeat surgery), which can range between 30% and 60% at 10 years,^{19,20} patient-prosthesis mismatch,²⁵ and lifestyle modification.

The Ross procedure (pulmonary autograft) and aortic homograft root replacement represent alternative approaches. The latter should be mainly restricted to cases of acute endocarditis with destruction of the aortic root because of limited durability and homograft calcification over time.²⁶ A meta-analysis²⁷ of observational studies of the Ross procedure in adults has shown a perioperative mortality of 3.2%, and linearized rates of late mortality (0.64% per year), structural and nonstructural deterioration of the pulmonary autograft (0.78% per year), and right ventricular outflow conduit (0.55% per year) and thromboembolism, bleeding, and valve thrombosis (0.36% per year). In one randomized controlled trial²⁸ of 216 adult patients that compared the Ross procedure with homograft, the surgical mortality for the Ross procedure was < 1%, 13-year survival in the Ross group was 95% and similar to the age- and sex-matched British population. Selected contemporary long-term cohort studies²⁹⁻³³ on outcome into the second decade have shown similar results in terms of late survival (Supplemental Table S3). Disadvantages include technical complexity of the procedure, transforming a single valve disease into 2-valve disease, and late rates of repeat surgery,³⁴ particularly in patients who present with aortic regurgitation and a dilated annulus.

RECOMMENDATION

4. For patients with aortic dilatation who require aortic valve replacement, we recommend using a mechanical or biological prosthesis (Strong Recommendation, Medium-Quality Evidence).

Values and preferences. In young adults, there are concerns related to long-term survival, quality of life, and valve-related complications.

5. We recommend that the Ross procedure be considered as an alternative for prosthetic valve replacement in young adults with bicuspid and tricuspid aortic valve stenosis and aortic dilatation (Strong Recommendation, Medium-Quality Evidence).

Values and preferences. The Ross procedure is most appropriate in patients with high levels of physical activity, those contemplating pregnancy, and patients with small aortic annuli at risk of patient-prosthesis mismatch. An important consideration is the ability to perform this procedure with mortality and morbidity similar to composite valve and root replacement procedures. Patients with aortic regurgitation and a dilated

annulus might be at higher risk of a late procedure. Connective tissue disease or inheritable thoracic aortic aneurysms are contraindications for the Ross procedure. This recommendation elicited varied opinions from the panelists, and was ultimately approved by a majority rather than unanimity.

Perfusion Strategies for Aortic Arch Surgery

Cannulation strategies

Commonly used arterial cannulation sites include the distal ascending aorta, right axillary, innominate, and femoral arteries. Alternatives include the carotid artery, and left ventricular apex (acute type A dissection).^{35,36} Right axillary artery or innominate artery cannulation have the distinct advantage of sequential use for antegrade cerebral perfusion (ACP). Special considerations regarding the arterial cannulation site should be made in patients with acute type A aortic dissection, because malperfusion is common and the site of arterial cannulation might improve overall perfusion or worsen malperfusion depending on flow dynamics.

Cerebral perfusion strategies

ACP and retrograde cerebral perfusion were developed as adjuncts to hypothermia for brain protection to allow safer and longer duration of circulatory arrest. Deep hypothermic circulatory arrest (DHCA), defined by core temperature of 14°C-20°C³⁷ was pioneered by Griep et al. in 1975, to improve safety of arch surgery.³⁸ A few landmark series have shown that DHCA alone yields "acceptable" rates (2%-7%) of permanent neurological deficit when circulatory arrest times are < 40-50 minutes.³⁹⁻⁴¹ Rates of transient neurological dysfunction have been shown to increase after 30 minutes of straight DHCA.⁴² A 2013 meta-analysis of observational studies reported significantly lower incidence of permanent neurological dysfunction (12.8% vs 7.3%; $P < 0.001$) with moderate hypothermia and ACP vs deep hypothermia alone. There was no significant difference in mortality in this meta-analysis (13.5% vs 11.1%).⁴³

ACP strategies, involving perfusion via the innominate and/or carotid arteries, were developed with the recognition that it was impossible to reduce cerebral metabolic consumption to 0 with hypothermia alone.⁴⁴⁻⁴⁶ Right axillary artery cannulation,⁴⁷ through a separate infraclavicular incision, facilitates central perfusion and unilateral ACP without manipulating the ascending aorta.⁴⁷⁻⁵⁰ Despite concerns about an incomplete Circle of Willis in some patients, bilateral ACP has not shown superiority to unilateral selective ACP strategies.⁵¹ ACP is typically carried out under varying degrees of hypothermia and lower body circulatory arrest at a flow rate of 10-15 mL/kg/min with a target right radial arterial pressure of 50-70 mm Hg.⁴⁵ Brain perfusion monitoring with continuous near-infrared spectroscopy, electroencephalography, and transcranial Doppler might guide adjustment in flows or need for bilateral ACP.

Adjunctive retrograde cerebral perfusion via the superior vena cava provides the theoretical benefits of cerebral cooling and removal of atheromatous debris during aortic arch surgery,^{52,53} but might have limited nutritive benefit beyond DHCA alone.^{54,55}

Temperature management

Although deep hypothermia is protective, adverse effects on organ function, the coagulation system, and need for prolonged cardiopulmonary bypass time remain important limitations. With the advent of ACP, aortic arch surgery is increasingly being performed under lesser degrees of hypothermia with potentially less morbidity.^{56,57}

RECOMMENDATION

6. We recommend right axillary artery cannulation or innominate artery cannulation be considered for complex aortic arch reconstruction or acute type A aortic dissection repair to facilitate ACP (Strong Recommendation, Medium-Quality Evidence).

Values and preferences. Axillary artery cannulation might not be preferred when the axillary artery is dissected, atherosclerotic, of small calibre, or in patients who are hemodynamically unstable. In acute type A aortic dissection, frequent reassessment of the adequacy of systemic perfusion using cerebral oximetry, upper and lower extremity arterial pressure, and transesophageal echocardiography is critical to avoid dynamic malperfusion.

7. We suggest deep hypothermia alone be considered as an isolated brain protection strategy for shorter durations of circulatory arrest (< 30 minutes) (Weak Recommendation, Medium-Quality Evidence).

Values and preferences. Deep hypothermia might be associated with deleterious side effects.

8. We recommend ACP be used when the anticipated duration of circulatory arrest is > 30 minutes to help preserve brain function (Strong Recommendation, Medium-Quality Evidence).

Values and preferences. In acute type A dissection, ACP might provide an additional safety margin for brain protection, because an element of unpredictability might dictate more complex arch reconstruction requiring > 30 minutes.

9. We suggest lesser degrees of hypothermia may be used for aortic arch procedures when ACP strategies are used (Weak Recommendation, Medium-Quality Evidence).

Values and preferences. Consideration should be given to the anticipated duration of distal organ ischemia with greater degrees of hypothermia used for longer duration of lower body arrest.

Extended Distal Repair for Type A Aortic Dissections

Unless contraindicated, the treatment of acute type A aortic dissection is surgical repair.⁵⁸ An open distal anastomosis has

become the standard surgical strategy,^{59,60} beveling the repair into the lesser curvature of the arch (hemiarch repair) with an open distal anastomosis during a period of circulatory arrest. Indications and techniques for a more extensive distal repair are currently evolving and are more controversial.

Rationale for extended distal repair

The goals of extended distal repair are to seal tears extending beyond the transverse arch and improve false lumen obliteration in the descending aorta. Theoretical benefits include prevention of early and late complications including reduced early malperfusion and late distal aortic dilatation, aortic reintervention, and mortality.

In the acute setting, patients who present with documented distal malperfusion have up to a fivefold increased mortality.⁶¹ Detection of malperfusion might be a challenging clinical diagnosis and the true incidence of malperfusion is likely underestimated.

In addition, up to 30% of patients might have a primary intimal tear distal to the ascending aorta.⁶² Resection of the intimal tear is one of the principles of surgical repair of dissection and these distal tears are not resected using standard “hemiarch” repair. Although resection of the intimal tear is thought to be of benefit, the evidence is equivocal, with a decreased repeat surgery

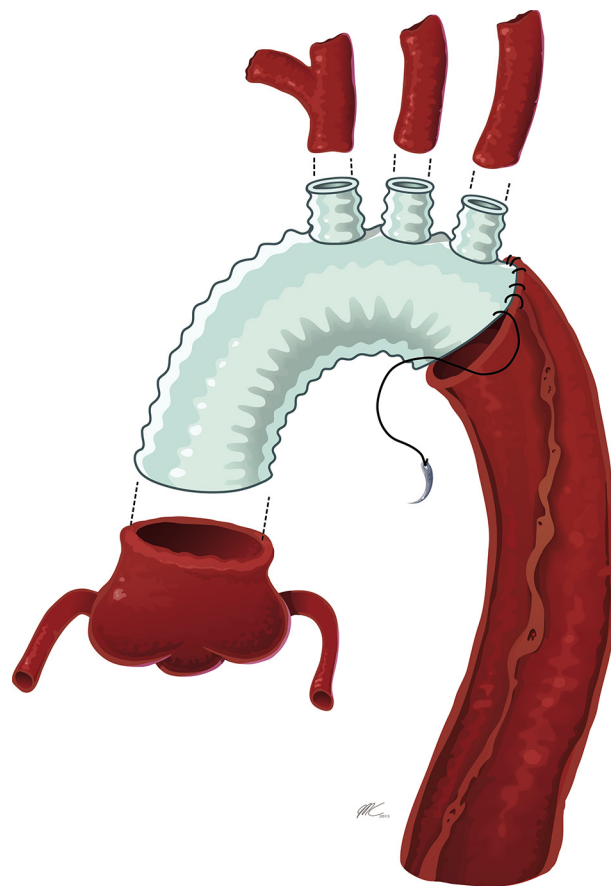


Figure 2. Conventional total arch replacement as a technique for extended distal aortic reconstruction in acute type A aortic dissection. A branched Dacron graft is used for individual end-to-end anastomosis of the arch vessels. Image courtesy of Dr Jehangir Appoo. Reprinted from with permission from www.aorta.ca.

rate observed in some reports,^{60,63-65} but not in others.⁶⁶ Furthermore, despite intimal tear resection, most patients are left with a patent false lumen after standard hemiarch repair.^{67,68} Patency of the residual false lumen might increase the risk of distal aorta repeat surgery and reduce long-term survival,^{69,70} although this has not been consistently observed.⁷¹

Techniques of extended distal aortic reconstruction for type A dissection

The conventional alternative to a “hemiarch” anastomosis is total arch replacement with or without elephant

trunk repair (Fig. 2). More recently, hybrid extended distal repairs involving the arch and descending aorta at the time of type A dissection have been developed. They consist of combined open surgical repair and endovascular aortic repair that eliminates any residual dissection in the arch and treats a varying amount of the descending aorta. These emerging techniques are depicted in Figure 3 and may be grouped into 3 categories that consider the extent of arch replacement, location of inflow to head vessels (orthotopic or extra-anatomic), and the method in which the stent graft is deployed (during circulatory arrest or after weaning from cardiopulmonary bypass):

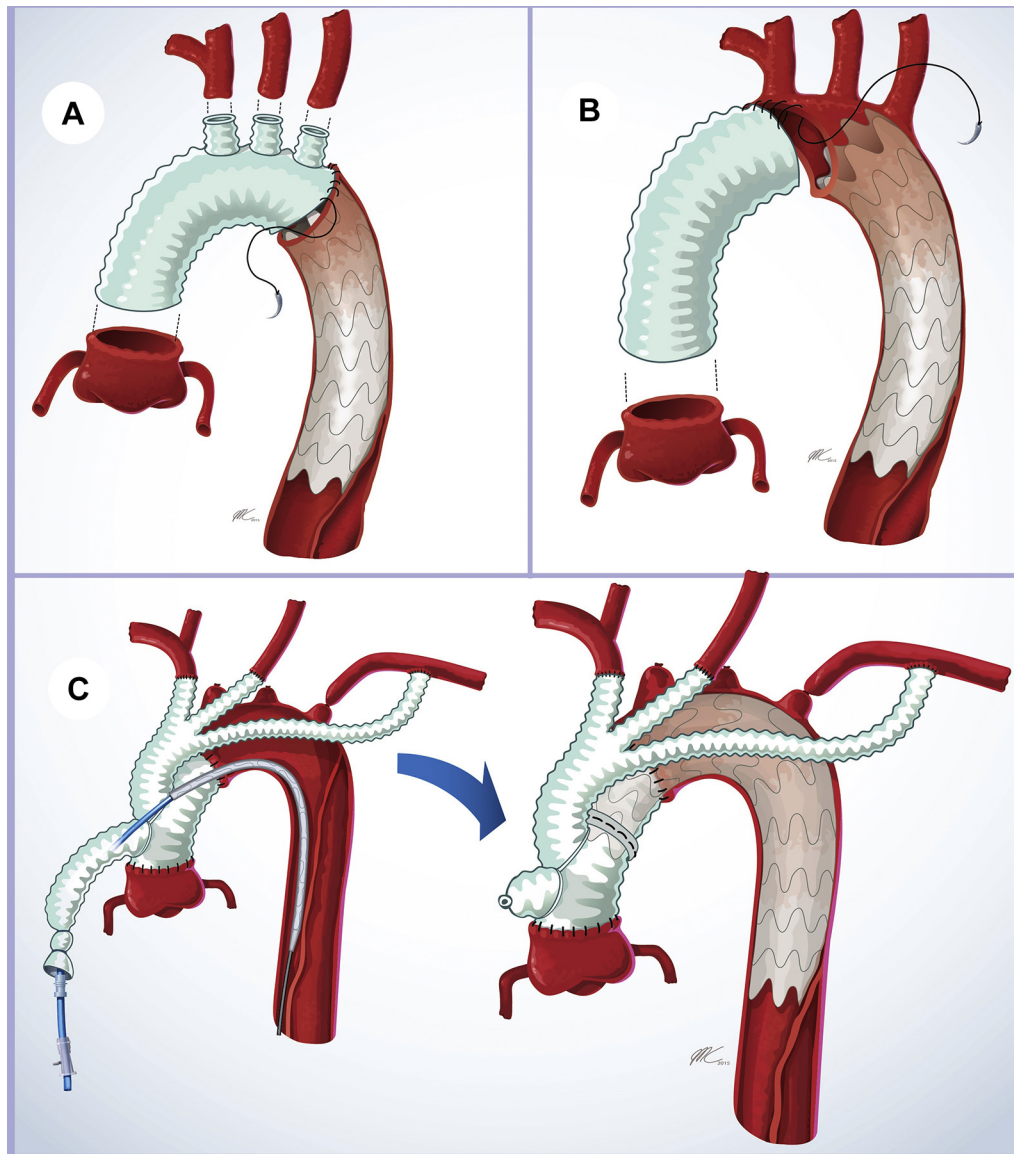


Figure 3. Categories of emerging hybrid surgical and endovascular techniques of extended distal aortic reconstruction for acute type A aortic dissection. **(A)** Frozen stent graft with total arch replacement: at the time of circulatory arrest, the stent graft is placed through the open aortic arch in an antegrade fashion into the descending thoracic aorta. Total arch reconstruction is then performed with a branched Dacron graft and individual head vessel reimplantation. **(B)** Frozen stent graft with hemiarch replacement: at the time of circulatory arrest, the stent graft is placed through the open aortic arch in an antegrade fashion into the descending thoracic aorta. Next, a standard hemiarch replacement is performed leaving an intervening segment of native dissected arch. **(C)** Arch debranching: the ascending aorta is replaced and proximal rerouting of arch vessels is done with a branched Dacron graft. After weaning from cardiopulmonary bypass, the stent graft is deployed across the arch and into the ascending aortic Dacron graft. Fluoroscopy is used to identify and evaluate landing zones. Image courtesy of Dr Jehangir Appoo. Reprinted from with permission from www.aorta.ca.

- (1) Total arch replacement with orthotopic arch vessel reimplantation and antegrade stent graft placed in the descending aorta at time of circulatory arrest.⁷¹⁻⁷⁴
- (2) Hemiarach replacement with antegrade stent graft placed in the descending aorta at time of circulatory arrest.⁷⁵⁻⁷⁹ The arch vessels and a short segment of the native arch are left in situ.
- (3) For arch debranching extra-anatomic proximal rerouting of arch vessels with ascending aortic replacement and stent graft deployment off pump with intraoperative fluoroscopy is used to determine landing zones.⁸⁰⁻⁸⁴ In this approach the stent graft may be deployed antegrade or retrograde.

There are no prospective trials on extended distal aortic repair compared with standard hemiarach replacement in acute type A dissections. All studies are small and rely on surgeon preference in the extent of distal replacement. Furthermore, these studies include a variety of repair techniques and a heterogeneous group of patients.^{64,65,85-88} Long-term outcomes, particularly the decision to repeat surgery on progressive pathology in the distal aorta are similarly surgeon-dependent, which makes comparisons prone to selection bias. [Supplemental Table S4](#) shows a summary of the contemporary results of extended distal repair for type A dissection and shows results that compare favourably with standard therapy. Contemporary registry data, mostly of standard “hemiarach repair,” reveals significantly improved mortality over a 17-year period (1995 to 2013) from 31% to 22%.⁸⁹ In 2012, the **German Registry for Acute Aortic Dissection Type A** (GERAADA) registry retrospectively compared 518 patients who underwent hemiarach replacement with 140 patients who underwent total arch replacement. All patients had a primary intimal tear in the ascending aorta. Because there was no significant difference in surgical mortality (18.7% vs 25.7%) and new postoperative stroke (13.6% vs 12.5%),⁹⁰ the authors concluded that a more aggressive approach to the arch can be carried out without increased perioperative mortality, with long-term benefit to be determined.

RECOMMENDATION

10. We recommend replacement of the ascending aorta during systemic circulatory arrest with an open distal anastomosis to be used routinely for repair of acute type A dissections (Strong Recommendation, Low-Quality Evidence).
11. We recommend that an extended distal arch repair technique be considered for patients who present with acute type A dissection and one of the following:
 - i. Primary intimal entry tear in the arch or descending aorta
 - ii. Significant aneurysmal disease of the arch (Strong Recommendation, Low-Quality Evidence).
12. We suggest that it is reasonable to consider an extended distal arch repair technique for patients who present with acute type A dissection and one of the following:

- i. Concomitant descending thoracic aortic aneurysm (DTAA)
- ii. Distal malperfusion
- iii. Young patients
- iv. Patients with known connective tissue disorders (Weak Recommendation, Low-Quality Evidence).

Values and preferences. Extended distal repair should only be offered if surgical safety is not compromised.

Contemporary Total Arch and Hybrid Arch Repair for Aneurysmal Arch Disease

Surgical procedures treating complex aortic arch pathology have evolved with improvements in perfusion management, resulting in reduced perioperative mortality and neurological injury.⁹¹⁻⁹³ Most contemporary series use the right axillary or innominate artery as the preferred arterial inflow, facilitating ACP and more moderate hypothermia. The original en bloc or island technique for arch vessels has been supplanted by the 4-branched graft technique of Kazui et al.⁹⁴ and the trifurcated or Y-graft technique proposed by Spielvogel and colleagues.⁹⁵ Both techniques permit bilateral ACP during the arch reconstruction and eliminate the diseased, often atheromatous aorta at the origin of the branch vessels. The location of the distal anastomosis, the management of the left subclavian artery, and the use of an elephant trunk are variable.

The optimal treatment strategy for extensive aneurysmal disease involving the ascending aorta, arch, and the descending thoracic aorta remains controversial. Open repair might be performed in 1 or 2 stages: (1) simultaneous repair of the arch and descending thoracic aorta through a clamshell (bilateral anterior thoracotomy and transverse sternotomy) incision; or (2) total arch elephant trunk procedure via sternotomy followed by a second stage open or endovascular completion. Hybrid repair of arch pathologies has been considered a less invasive method and although the techniques are heterogeneous, they share a common goal of extending the suitable proximal landing zone more proximally for deployment of a stent graft. Hybrid approaches may be performed with or without cardiopulmonary bypass, and with or without circulatory arrest. A normal calibre ascending aorta is required for debranching to be done off-pump, whereas patients with ascending aortic pathology require cardiopulmonary bypass to replace the ascending aorta, debranch the arch vessels, and create a proximal landing zone in the Dacron graft distal to the origin of the debranched vessels ([Fig. 3C](#)). An alternative hybrid approach involves open replacement of the arch and placement of a stent graft in the descending aorta under direct vision at the time of circulatory arrest, a technique known as “frozen elephant trunk” ([Fig. 3A](#)).

The heterogeneity of techniques and small cohort sizes of the reported studies have made meaningful comparisons of hybrid techniques with open repair difficult. An international aortic arch surgery group has reported standardization of clinical end points to facilitate evaluation of various techniques for arch repair.⁹⁶

RECOMMENDATION

13. We suggest that hybrid arch repair be considered in patients deemed too high-risk for conventional open repair who meet specific anatomic criteria (Weak Recommendation, Low-Quality Evidence).

Values and preferences. Stroke is a significant risk in conventional and hybrid techniques. Creation of an optimal straight landing zone in Dacron or native aorta is desirable for stent graft technology available today. Ascending aortic diameter ≥ 4 cm is a risk factor for retrograde type A dissection. Hybrid arch repair should be avoided in patients with known or suspected connective tissue disorders unless proximal and distal landing zones are in Dacron replaced aorta.

14. We suggest that hybrid arch techniques might be considered for single-stage repair in patients with diffuse aneurysms involving the ascending, arch and descending aorta (mega aorta) (Weak Recommendation, Low-Quality Evidence).

Total Endovascular Arch Repair

Although open repair remains the gold standard, several strategies have been developed for a closed-chest approach to aortic arch aneurysms (Supplemental Table S5). These include:

1. Chimney technique: a covered endovascular stent graft placed across the arch with parallel stents deployed in the arch branches.^{97,98}
2. In situ fenestration: a covered endovascular stent graft is first placed across the arch and then fenestrations created for perfusion of the branch vessels. This technique has usually been reserved for the left subclavian artery.⁹⁹
3. Custom-made fenestrated or branched endografts.¹⁰⁰⁻¹⁰²

All techniques require direct cannulation of the arch vessels with the inherent risk of stroke which has occurred in up to 11.5% of cases,^{97,100} and early mortality rates up to 16.5%.¹⁰⁰ A recent series from Japan described 383 patients treated with a precurved fenestrated arch endograft with a 1.6% 30-day mortality rate and 1.8% stroke rate.¹⁰² There are no randomized or high-quality comparative studies on total endovascular vs open repairs.

Recently, an international, multicentre group reported on a double inner branched arch endograft in 38 high-risk patients with arch aneurysms.¹⁰⁰ This experience reflects the steep learning curve with these advanced endovascular techniques with a 30-day mortality rate of 30% for the first 10 cases, improving to 7.1% in the next 28 cases.¹⁰³ Endoleaks occurred in one-third of patients and an ascending aortic diameter larger than 38 mm was associated with adverse events. Long-term results are unknown.

RECOMMENDATION

15. We suggest that closed-chest arch reconstructions only be considered for patients at high risk for open or hybrid repair (Weak Recommendation, Low-Quality Evidence).

Values and preferences. Anatomic factors to consider include the presence of dissection flap, orientation of arch vessels, and proximal and distal landing zones. Total endovascular repair for aortic arch aneurysms should be performed by a multidisciplinary team with sufficient clinical and technical experience with open repair and advanced endovascular techniques. Fixed imaging systems are beneficial for advanced endovascular techniques.

DTAAs

DTAA, between the origins of the left subclavian artery and the celiac artery (Fig. 4), occur in 10.4 per 100,000 population with a similar incidence between sexes.¹⁰⁴ The introduction of thoracic endovascular aortic repair (TEVAR) has resulted in increased rates of emergent and elective repair of DTAAs in the United States.¹⁰⁵ This increased uptake has resulted in a decrease in surgical mortality and shorter hospital stays despite older patients with higher degrees of comorbidities.¹⁰⁶ Major complication rates of TEVAR include 5%-6% mortality, 3%-5% stroke, 2%-3% spinal cord ischemia, and 1%-6% retrograde type A dissection.¹⁰⁷ Multispecialty guidelines recommend that TEVAR be strongly considered for DTAAs when surgery is indicated on the basis of absolute diameter or relative aortic size.^{108,109}

Although there are no randomized controlled trials, there is a growing body of literature involving observational studies on TEVAR compared with open repair,^{96,110-118} systematic reviews,¹¹⁹ and a recent Cochrane review.¹²⁰ Findings of these comparative studies have consistently reported short-term advantages to TEVAR including lower mortality rates, shorter length of hospitalizations, and lower rates of paraplegia or neurologic complications. In a recent systematic review, TEVAR was shown to reduce perioperative mortality (pooled odds ratio 0.25; 95% confidence interval, 0.09-0.66) and risk of major neurologic morbidity (pooled odds ratio, 0.28; 95% confidence interval, 0.13-0.61) in patients with DTAAs.¹¹⁹

These short-term benefits are countered by secondary interventions for situations unique to endovascular repair, including endoleak, aneurysm sac expansion, and endograft migration. Up to 10% of patients will require secondary endovascular reinterventions after initially successful TEVAR for DTAAs, most commonly for attachment site (type 1) endoleaks.¹²¹ Because of the need for ongoing surveillance and these secondary interventions, TEVAR has not been observed to be cost effective compared with open repair.¹²² However, when the reduction in the incidence of paraplegia and the associated costs of this complication are included, TEVAR becomes a more cost effective therapy.¹²³ Despite higher survival rates and lower paraplegia rates, long-term quality of life indices are not improved after TEVAR compared with open repair, possibly reflecting the anxiety around surveillance and secondary interventions.¹²⁴ Despite these longer-term concerns, TEVAR has become the preferred mode of therapy of DTAAs.⁹⁶ Authors of the recent Cochrane review had similar views but also recommended a randomized controlled trial, a viewpoint that is not universal.¹²⁰

Patients with underlying connective tissue disorders have poorer outcomes with TEVAR and higher rates of secondary interventions. Figure 4 shows the landing zones of attachment in the thoracoabdominal aorta.¹²⁵

RECOMMENDATION

16. We recommend DTAAAs with appropriate anatomy and etiology be treated with thoracic endovascular repair (Strong Recommendation, Medium-Quality Evidence).

Values and preferences. Open repair is considered the first option in patients with a known connective tissue disorder who undergo elective surgery and in patients who do not have suitable landing zones for endovascular techniques.

Type B Aortic Dissection

Aortic dissections are divided into type A, which involves the ascending thoracic aorta, and type B, which typically begins immediately at or beyond the left subclavian artery.¹²⁶ Historically, a dissection is labelled acute in the first 2 weeks of onset. Beyond 2 weeks a dissection is termed chronic, although several newer classification schemes have proposed the period between 2 weeks and up to as late as 90 days after the initial event as subacute.¹²⁷⁻¹²⁹

Acute type B dissection—complicated

A dissection is considered complicated when there is evidence of leak, rupture, rapid aortic expansion, or malperfusion, which might involve the spinal cord, mesenteric and renal branches, or peripheral limb ischemia. Persistent intractable pain and refractory hypertension are also considered features of a complicated dissection, which can usually be controlled with medical therapy. Ischemia in any distal perfusion bed can occur from a dynamic or static obstruction.¹³⁰⁻¹³² Untreated complicated type B aortic dissection usually results in irreversible end organ damage or death.¹³³⁻¹³⁶

Historically, results with open surgery via thoracotomy were poor and open aortic replacement was only attempted in cases of leak or rupture.¹³⁷ End organ ischemia was dealt with circuitously with a variety of procedures to create communications between true and false lumens and extra-anatomic bypasses, all aimed at avoiding open thoracic aortic surgery,^{133,138} although open fenestration via thoracotomy remained an option.¹³⁹

Endovascular repair has now become first-line therapy for acute complicated type B dissections.¹⁴⁰ Goals of TEVAR in this context are to cover the primary intimal tear, reverse malperfusion syndromes, and promote thrombosis of the false lumen with subsequent aortic remodelling. Mossop and Nixon and colleagues¹⁴¹ introduced the idea of a distal uncovered (“dissection”) aortic stent to scaffold the remaining distal true lumen and promote aortic healing without compromising branch vessel flow. A multicentre¹³⁸ single-arm prospective study, the Study for the Treatment of Complicated Type B Aortic Dissection Using Endoluminal Repair (STABLE) trial,¹⁴² reported favourable clinical and anatomical results with this strategy. The population studied was mixed, with a number of cases considered chronic complicated dissections. Two-year follow-up showed a 30-day mortality of 5.5% in patients who presented acutely. All-cause mortality was 12% at 1 year and 15% at 2 years. Gradual expansion of the true lumen and contraction of the false lumen was observed.

Acute type B dissection—uncomplicated

In the absence of complicating features, an acute type B dissection is considered “uncomplicated.” Some have suggested that “uncomplicated” is a misnomer, because of the longer-term natural history showing aortic expansion and late complications. There is ongoing debate regarding the ideal initial management of this entity.

All cases of aortic dissection require optimal medical treatment (OMT), usually in a critical care setting, which includes arterial blood pressure and pain control, and frequent imaging surveillance of the aorta. Although there is some debate regarding the optimal pharmacological agents and hemodynamic targets,¹⁴³⁻¹⁴⁵ a blood pressure < 120/80 mm Hg, achieved using β -blockers as first-line agents, is widely accepted because of the theoretical benefit of reducing aortic wall shear stress. Early repeat imaging surveillance, typically at 48-72 hours and then again at 1-4 weeks, is an important component of medical therapy. The **Investigation of Stent Grafts in Patients with Type B Aortic Dissection (INSTEAD)** trial, which randomized 140 patients with uncomplicated type B aortic dissection in the subacute and chronic phases (2-52 weeks; mean, 10-12 weeks) to OMT or OMT with TEVAR, showed no difference in all-cause or aorta-related mortality between groups (96% vs 89%) at 2 years, but was underpowered for this end point.¹⁴⁶ Aortic remodelling was greatly improved in the stented group with false lumen thrombosis or expansion of true lumen occurring in 91% vs 19% in the TEVAR with OMT vs OMT alone groups. A longer-term landmark analysis (**Investigation of Stent Grafts in Aortic Dissection With Extended Length of Follow-up [INSTEAD-XL]**) showed a greater incidence of aortic dilatation (66% vs 21%), reduction in false lumen thrombosis (22% vs 91%), and poorer aortic remodelling (10% vs 80%), in the OMT-alone group after 5 years.¹⁴⁷ The **International Registry of Acute Aortic Dissection (IRAD)** registry used observational data to show significantly improved aorta-related survival in stented vs OMT alone at 5 years¹⁴⁸ even though other studies have failed to show any advantage.¹⁴⁹ The **Acute Dissection: Stent Graft or Best Medical Therapy (ADSORB)** trial randomized 61 patients to OMT or OMT with TEVAR with covered stent, and showed early benefits to stenting with respect to aortic remodelling.¹⁵⁰

Optimal management of uncomplicated acute type B aortic dissections might require a tailored approach to identify those at risk for late aneurysmal degeneration of the thoracic aorta. In a review of 18 studies that reported on predictors of aortic growth,¹⁵¹ younger age was associated with an increased growth rate.¹⁵² Less aortic growth was observed in the Asian population.¹⁵³ An increase in the level of fibrinogen degradation products was predictive of growth, but has not been widely studied.¹⁵⁴ Multiple studies consistently identified an initial aortic diameter of > 4 cm as predicting eventual further enlargement^{149,155,156} although others have shown the opposite.¹⁴⁸ An initial false lumen diameter of > 22 mm,¹⁵⁷ a convex appearance (concave true lumen),¹⁵² or a proximal saccular shape were all predictors of poor outcome. The number¹⁵⁸ and size¹⁵⁹ of entry tears were also predictive of growth; with a single large tear¹⁵⁹ (≥ 1 cm) being most ominous.

RECOMMENDATION

17. We recommend that endovascular repair be first-line therapy for complicated type B aortic dissections to reduce mortality and morbidity (Strong Recommendation, Medium-Quality Evidence).

Values and preferences. A covered stent graft to exclude the intimal tear is the primary goal. Adjunctive procedures might include distal coverage, uncovered stents, fenestration, or branch vessel stenting. Open surgery is reserved for failure or technical nonfeasibility of endovascular repair. In patients with connective tissue disorders, a tailored approach might be required with initial TEVAR and subsequent close follow-up for possible delayed open repair. Successful correction of malperfusion should be confirmed.

18. We recommend that patients with uncomplicated acute type B aortic dissections be managed with hypertension and pain control and radiologic surveillance (Strong Recommendation, Medium-Quality Evidence).

Values and preferences. If patients remains “uncomplicated,” early follow-up imaging at 48-72 hours and 1-4 weeks is recommended to detect early signs of aneurysm expansion and radiologic malperfusion.

19. We suggest that endovascular repair be considered for patients with uncomplicated type B aortic dissections to improve aorta-specific end points (Weak Recommendation, Low-Quality Evidence).

Values and preferences. The INSTEAD XL trial, which randomized patients in the delayed phase (2-52 weeks) showed decreased aorta-specific 5-year mortality and improved aortic remodelling. The ADSORB trial, which randomized patients in the acute phase (< 2 weeks) showed improvement in aortic remodelling at 1 year.

Chronic type B aortic dissection

Type B aortic dissections are considered chronic at > 90 days after their onset. As the aorta remodels, in a subset of patients, the aorta and particularly the false lumen continues to expand. The most common indication for intervention is aneurysmal degeneration or rapid growth in an asymptomatic patient. Some patients might present with pain related to further extension, compression of adjacent anatomical structures, malperfusion, or rupture.

The classical treatment for these patients has been open surgery via thoracotomy, clamshell incision, or a thoracoabdominal approach. A number of large open surgical series from major centres of excellence have provided acceptable results, but typically reflect heterogeneous populations of mixed acuity and extent of aortic disease.¹⁶⁰⁻¹⁶⁹ In a series by Pujara et al.,¹⁶⁶ excellent results were realized with a 30-day mortality of 8% and an overall incidence of spinal cord injury of only 2.4%. They noted that greater initial preoperative aortic diameter, and a greater extent of disease were both predictive of worse outcome, making the case for earlier

intervention in chronic type B dissections. Although open surgery is effective, it carries a significant risk of perioperative mortality and morbidity.

More recently, endovascular approaches have been attempted in selected patients with chronic type B dissection, with the primary goal of sealing off the main entry tear and major re-entry tears, thereby promoting aortic false lumen thrombosis and facilitating aortic remodelling. The INSTEAD trial^{146,147} discussed previously, largely treated patients in the subacute phase but did include some chronic patients (up to 52 weeks). A number of observational cohorts have shown technical feasibility of TEVAR or hybrid (open debranching with TEVAR) procedures in selected patients with favourable anatomy.¹⁷⁰⁻¹⁷⁵ Persistence of false lumen perfusion from distal re-entry tears remains an important limitation. There is a paucity of data on open vs endovascular treatment of chronic type B aortic dissections.

RECOMMENDATION

20. We recommend that patients with chronic type B aortic dissections who have indications for repair and have acceptable surgical risk receive open surgical repair with consideration of endovascular or hybrid repairs reserved for patients with high surgical risk (Strong Recommendation, Medium-Quality Evidence).

Values and preferences. Open surgery carries a significant risk of perioperative mortality and morbidity. An endovascular or hybrid approach might be considered in high-risk surgical patients. Endovascular approaches are at risk for persistent perfusion of the false lumen.

Options for the Distal Landing Zone

Commonly used thoracic endografts require a distal landing zone length of at least 15-25 mm of nondiseased distal descending thoracic aorta in zone 5 (Fig. 4). It is estimated that the supraceliac aorta is inadequate as a distal landing zone in 4%-15%¹⁷⁶ of patients with descending thoracic aneurysms. As a result, several strategies have been developed to extend this landing zone.

If a zone 6 (Fig. 4) landing zone is required, the celiac artery might occasionally be covered without revascularization in the presence of adequate collateral vessels between the celiac and superior mesenteric arteries as well as a patent portal vein.¹⁷⁶⁻¹⁷⁸ It should be noted that if complications develop and vasoconstricting agents are needed, then collaterals might no longer be adequate. When celiac artery perfusion is required and a short distance of additional aorta is needed, a scallop¹²⁵ can be placed at the distal aspect of the endograft and aligned with the celiac artery. When extension more distally into the visceral aortic segment is necessary, combinations of fenestrations and branches can be incorporated endograft designs.¹⁷⁹ Before the availability of off-the-shelf branched or fenestrated endografts, several groups recommended the deployment of balloon expandable covered stents

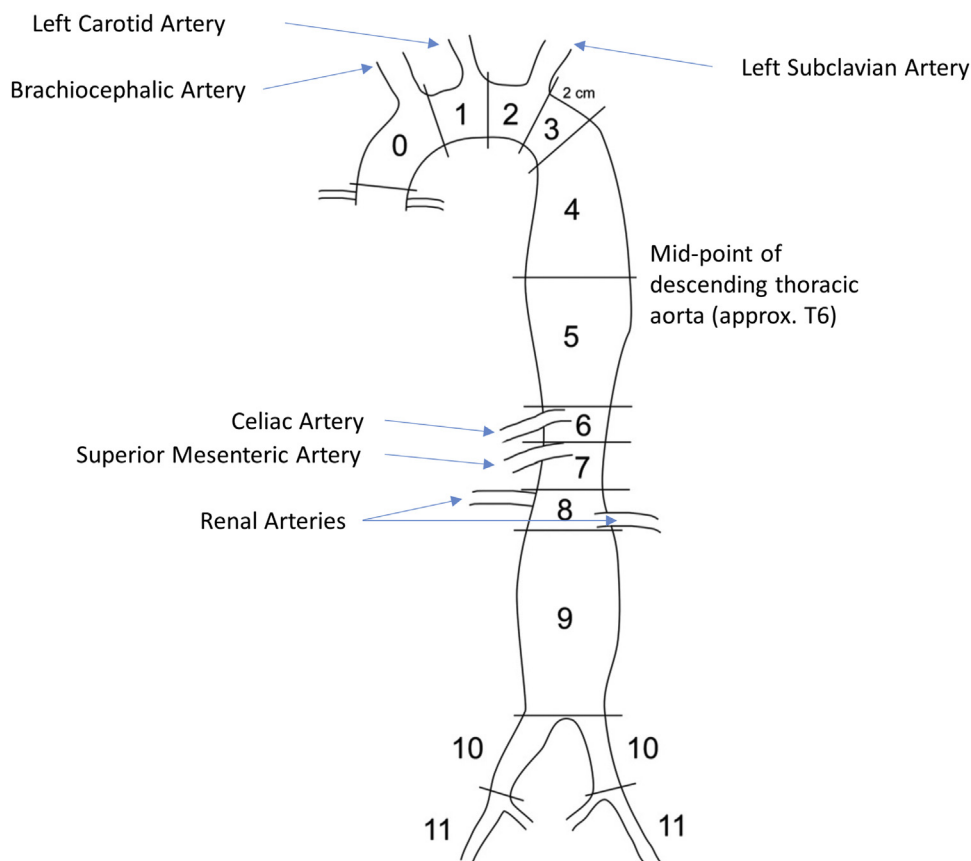


Figure 4. Zones of attachment in the thoracoabdominal aorta. Reprinted from Fillinger et al.¹²⁵ with permission from Elsevier.¹²⁵

parallel to a thoracic endograft in a snorkel or periscope configuration, especially in urgent situations.¹⁸⁰ In certain patients, a hybrid procedure is possible with a laparotomy and retrograde bypass to the visceral and renal arteries followed by TEVAR across their orifices.¹⁸¹ More recently, some experience has been reported with multilayer flow-modulating stents placed across the visceral and renal arteries during complex endovascular repairs, although their role continues to require study and clarification.¹⁸²

Conclusions

Open and endovascular interventions for thoracic aortic disease continue to evolve, resulting in improved patient outcomes. New surgical paradigms have allowed native valves to be preserved rather than replaced. Improved techniques of brain protection have permitted surgery on the aortic arch with greater safety. Endovascular technology has improved the safety of aortic surgery and extended the indications of minimally invasive thoracic aortic surgery. The combination of improved results with open surgery and endovascular treatment has allowed for simultaneous treatment of the aorta from the valve to the diaphragm. A concerted effort by burgeoning multidisciplinary aortic

clinical networks worldwide will help further define the future evolution of aortic surgery.

Acknowledgements

The authors thank the secondary panel members, Dr Joseph E. Bavaria (University of Pennsylvania), Dr Chad Hughes (Duke University), Dr Francois Dagenais (Laval University), Dr Thoralf Sundt (Harvard University), and Dr Mark Farber (University of North Carolina) for their expert review. We thank Susan Oliver and Huei-Ling Tsuei from the Canadian Cardiovascular Society for facilitating the process.

For a complete list of panel members, see [Supplemental Appendix S3](#).

References

All references are provided in [Supplemental Appendix S1](#).

Supplementary Material

To access the supplementary material accompanying this article, visit the online version of the *Canadian Journal of Cardiology* at www.onlinecjc.ca and at <http://dx.doi.org/10.1016/j.cjca.2015.12.037>.